

# Radiology Quiz

# Medical Students Workbook

Author: Dr Aussami Abbas

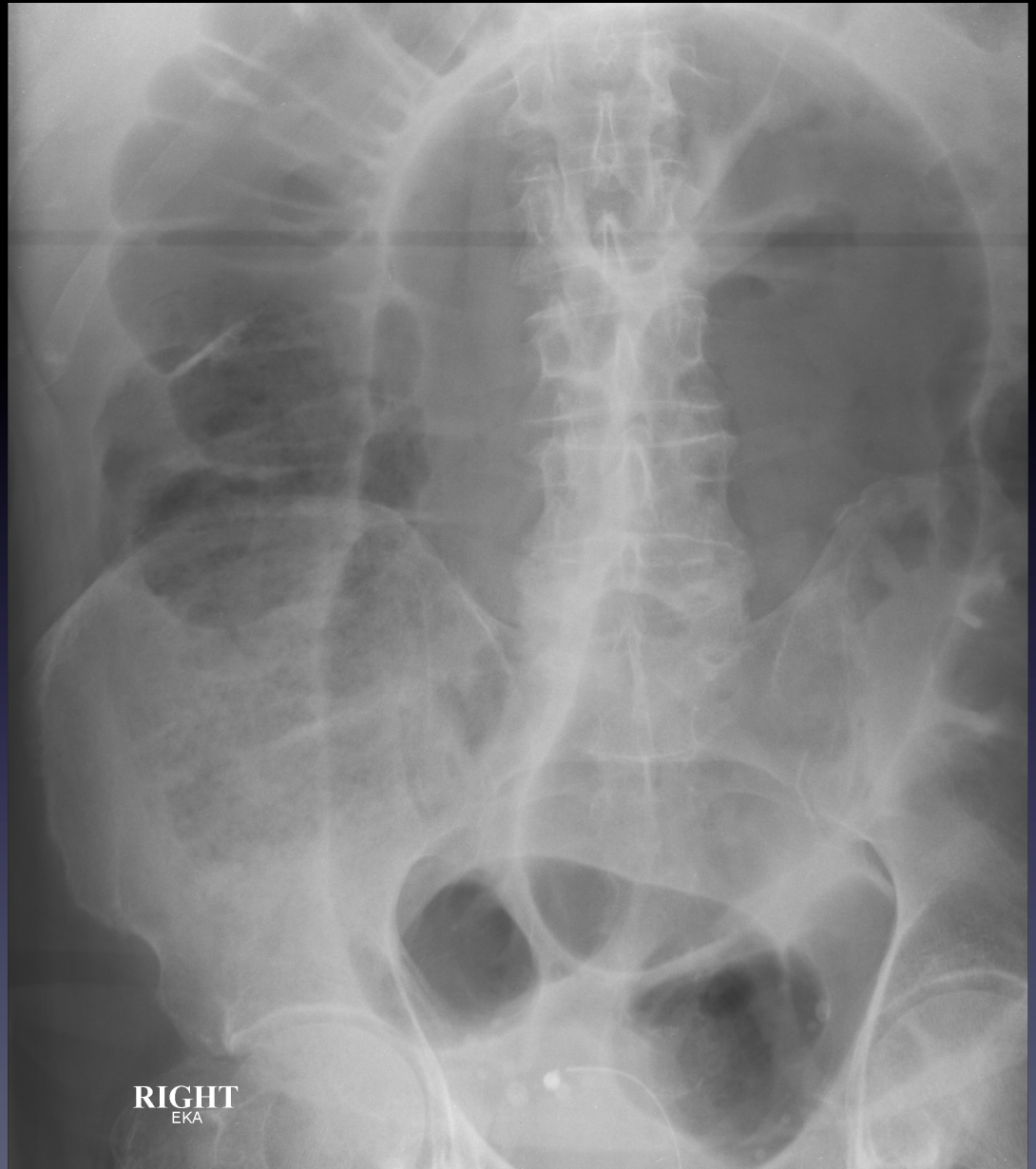
SpR Radiology

# Case 1

83 yr old patient presents  
with abdominal pain

Questions:

- 1) What is the diagnosis?
- 2) Name two possible complications.

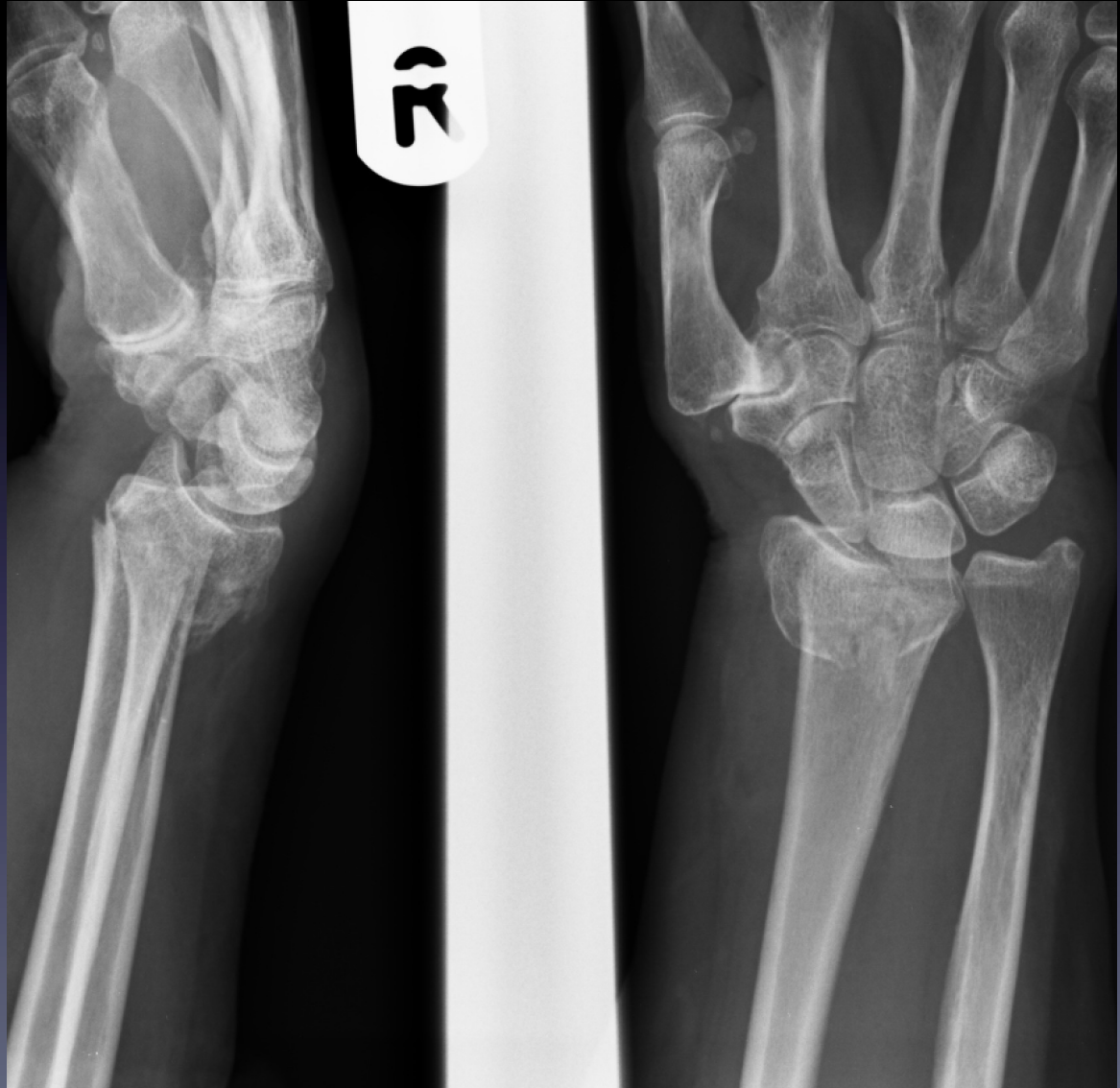

## Case 2

72 yr old patient presents with clinical deformity of the right wrist following a fall onto out stretched hand

Questions:

- 1) What is the diagnosis?
- 2) What is the clinical deformity associated with this injury called?
- 3) Name 2 methods of providing local anaesthesia for manipulation of this injury.
- 4) What degree of misalignment is acceptable following reduction?

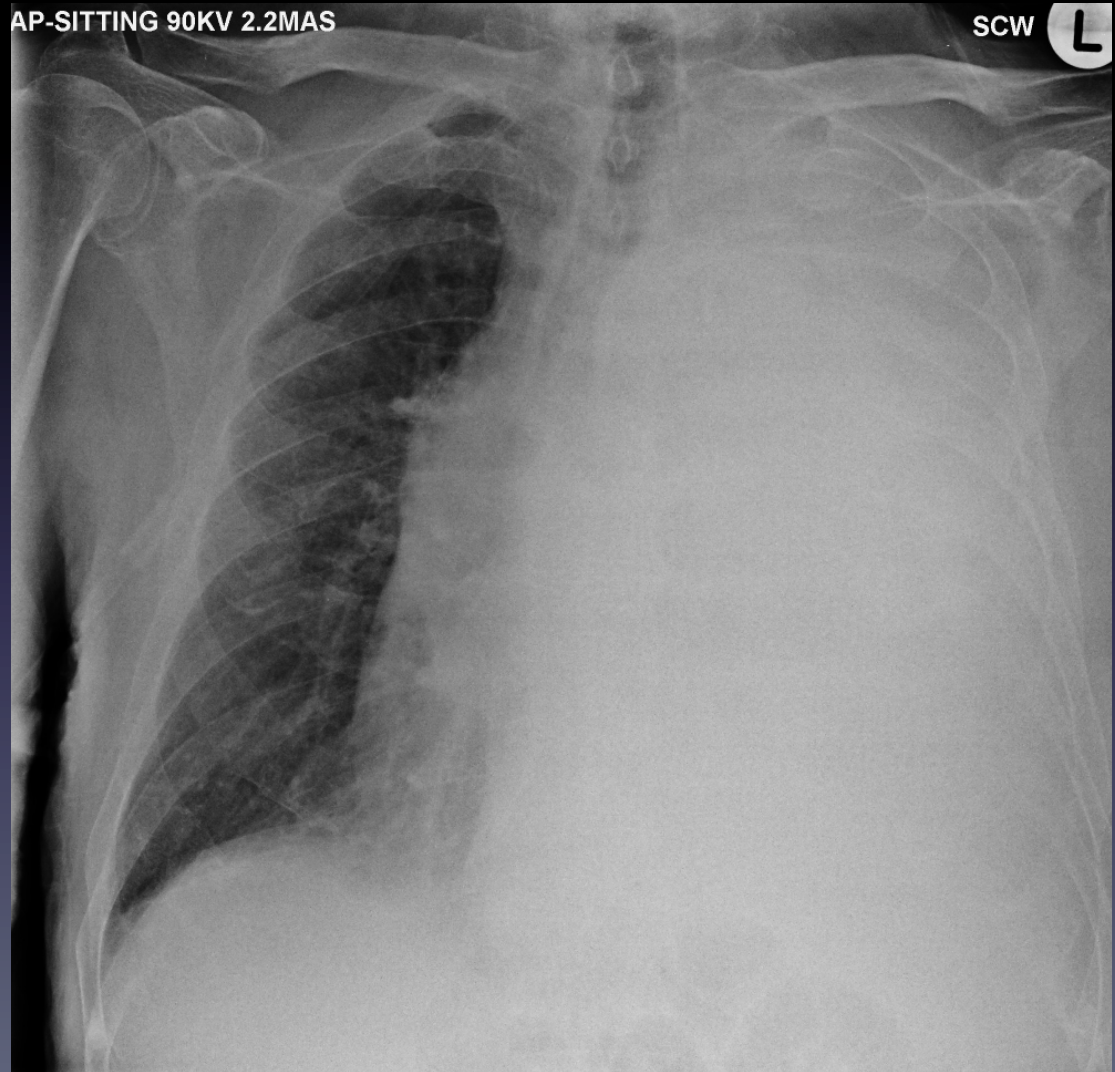


# Case 3

65 yr old patient on AMU develops worsening respiratory distress

Questions:

- 1) Name three causes for the appearance of a hemithorax “white out” on CXR.
- 2) How can you tell the difference between these three causes?
- 3) What is the diagnosis in this case?
- 4) What management should the patient have?

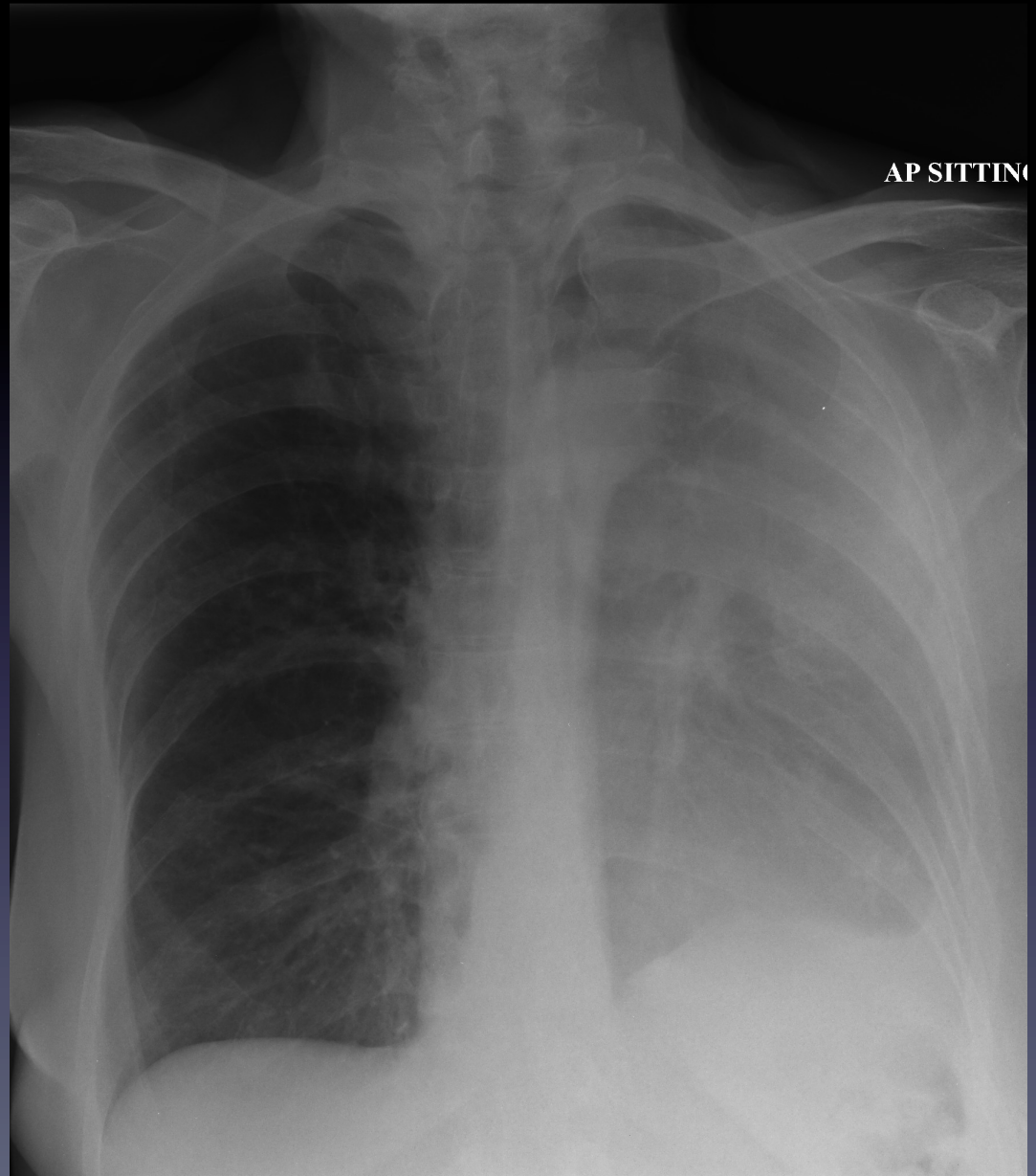


# Case 4

65 yr old patient presents with dyspnoea and cough

Questions:

- 1) What is the diagnosis?
- 2) What is the most likely cause
- 3) After ensuring the patient is clinically stable what further management would you arrange?



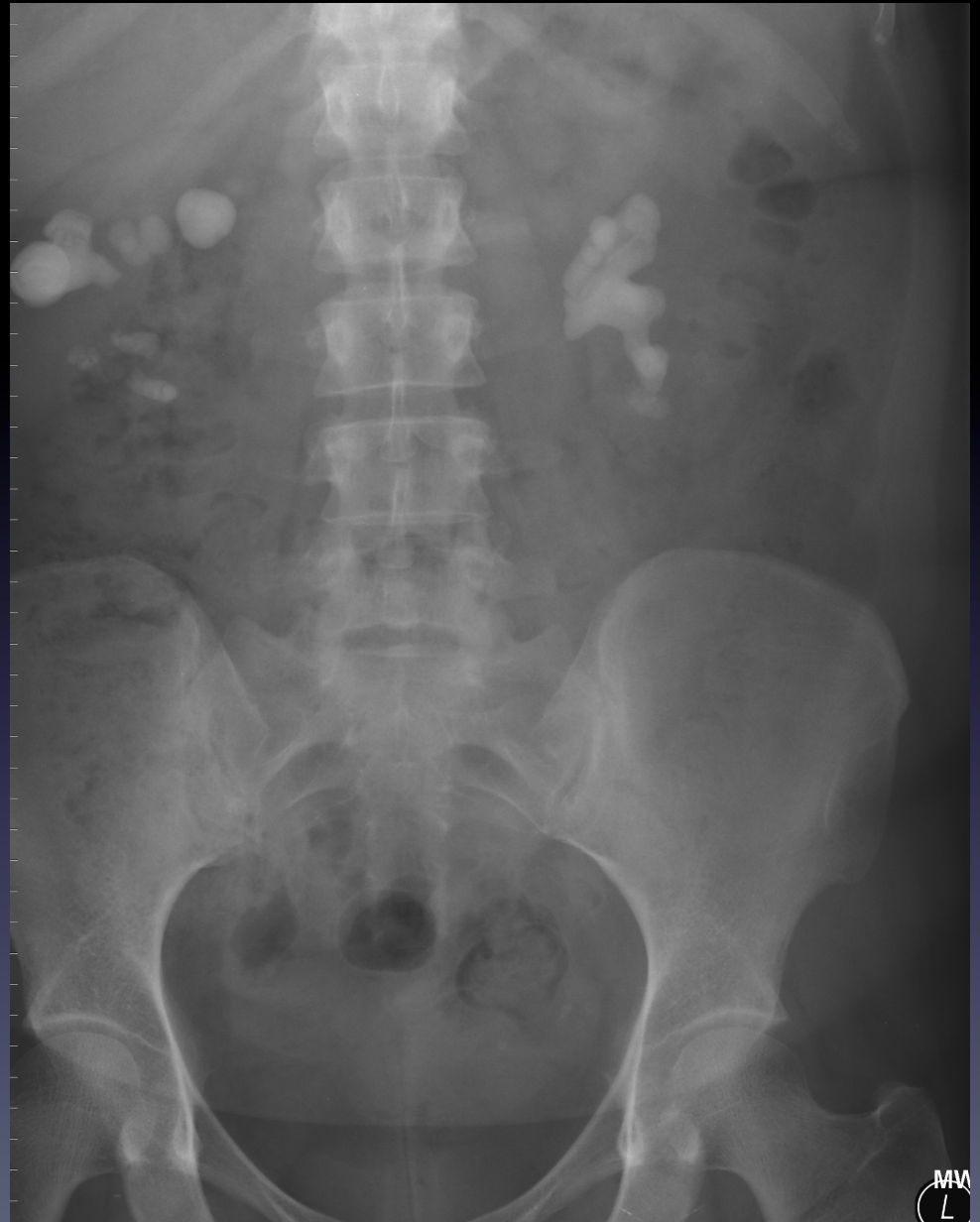

# Case 5

45 yr old patient presents with dysuria. A plain film radiograph is performed

Questions:

- 1) What is the diagnosis?
- 2) Which infectious organism is this associated with?

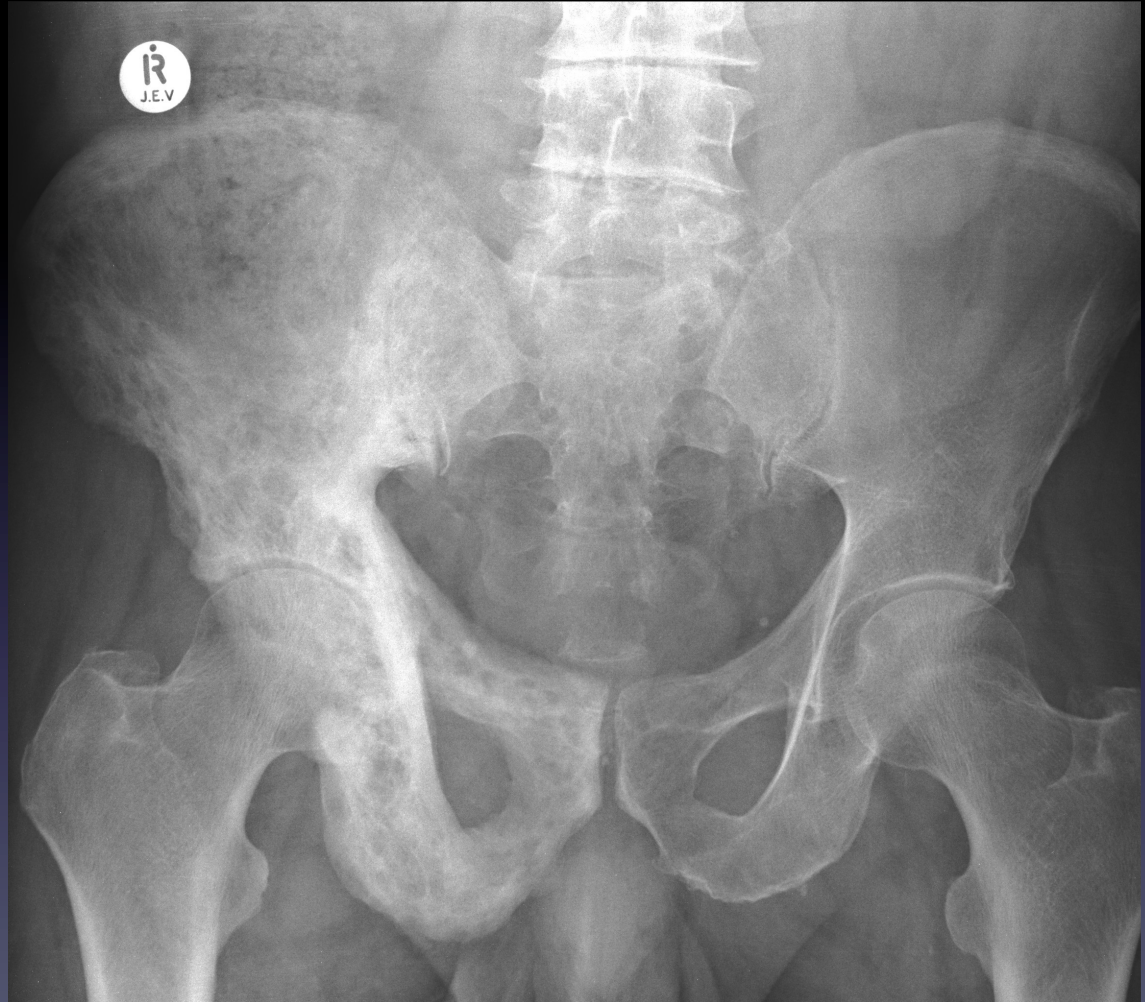

# Case 6

61 yr old patient presents  
With left hip pain

Questions:

- 1) What is the diagnosis?
- 2) Is this the cause of the patients symptoms
- 3) Name 3 complications associated with this condition
- 4) Name three other common sites of disease involvement.

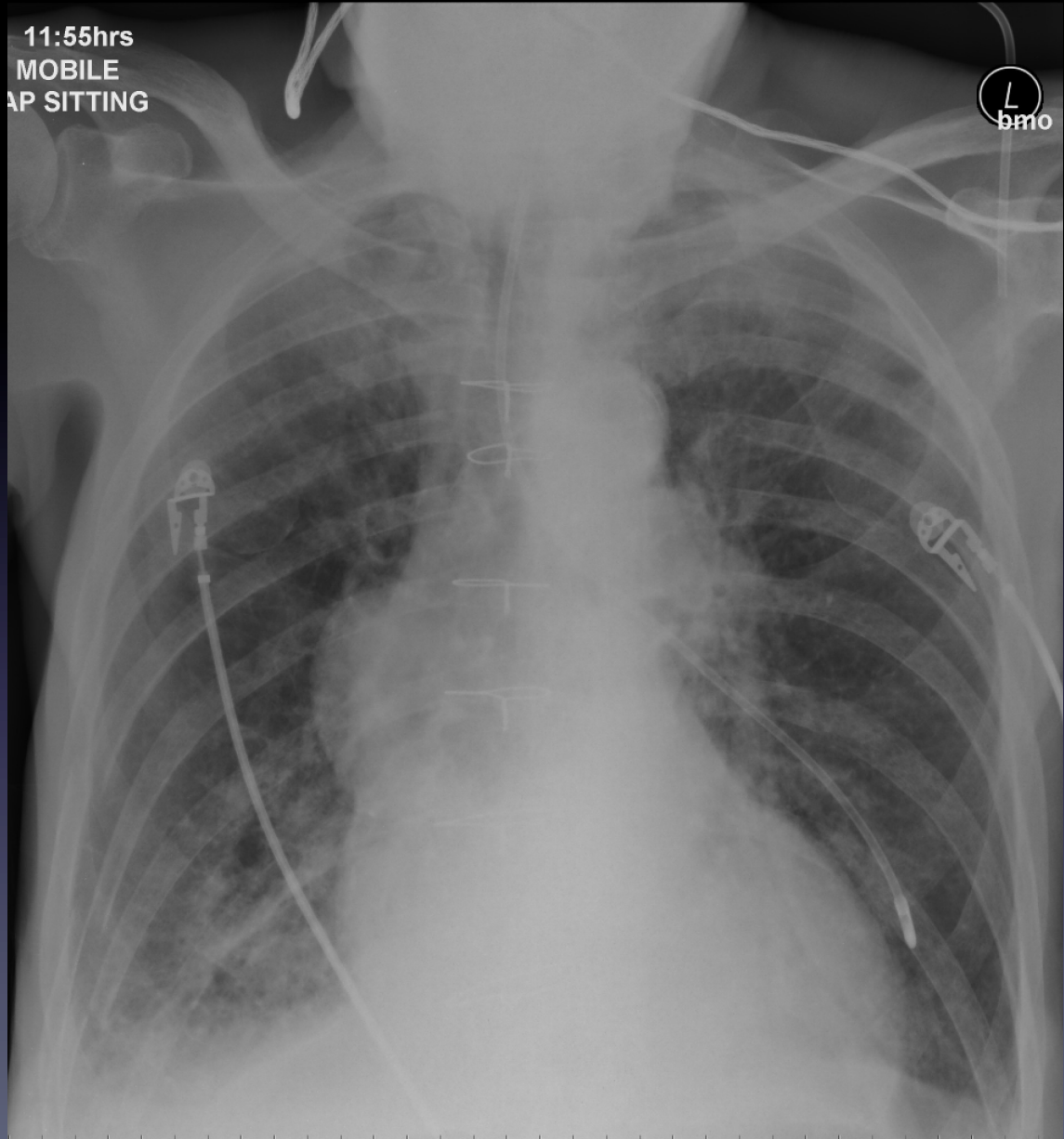


# Case 7

You are on call covering the medical wards. A colleague hands over to check a CXR on the stroke ward

Questions:

- 1) What is the main abnormality?
- 2) What instructions should you give the nursing staff on the ward?
- 3) What surgery has the patient had in the past?



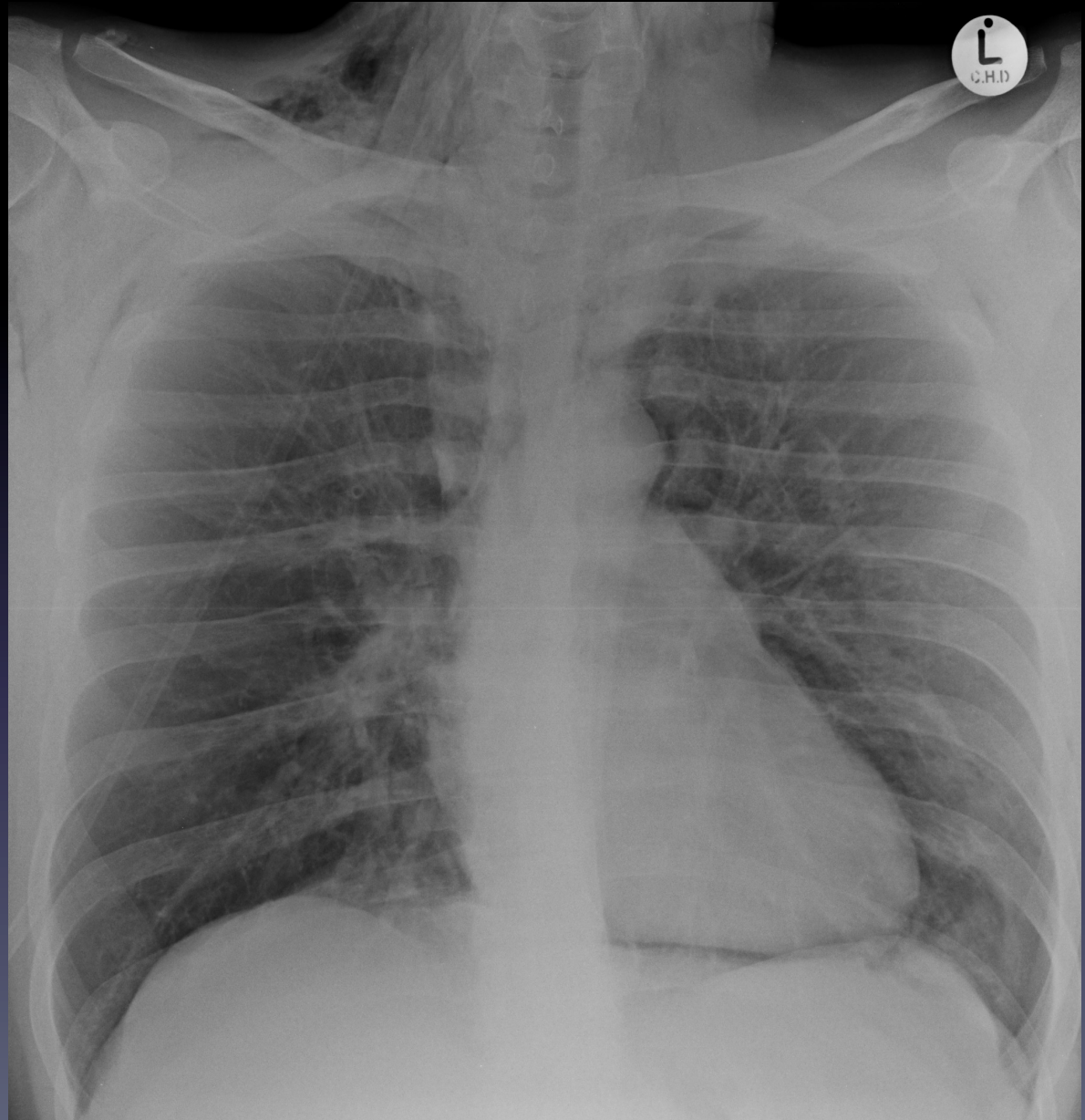


# Case 8

35 yr old asthmatic patient suddenly deteriorates on the ward

Questions:

- 1) What is the diagnosis?
- 2) Name four potential causes.
- 3) What is the most likely cause in this case?

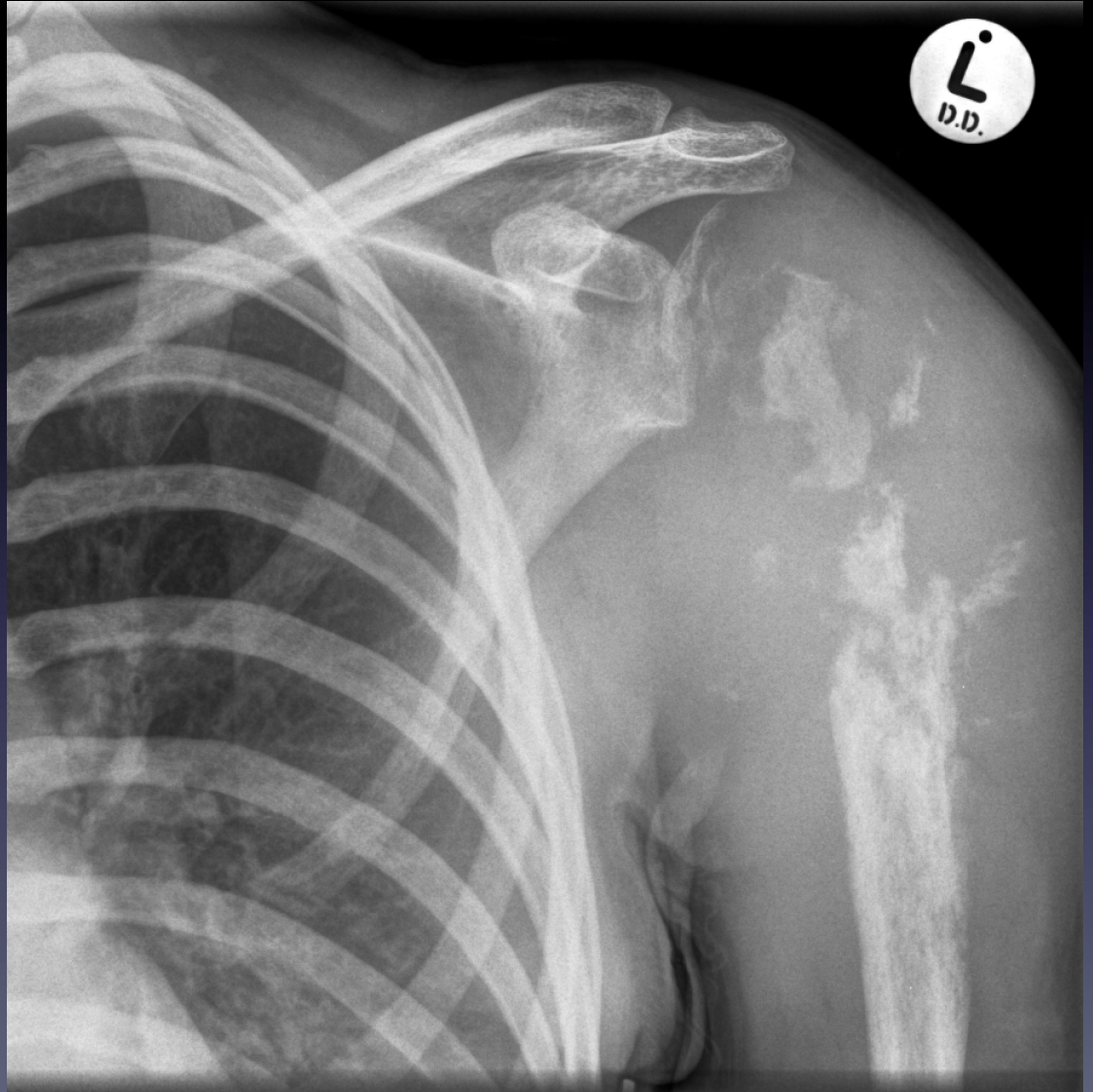


# Case 9

18 yr old patient presents with left shoulder pain and swelling

Questions:

- 1) What is the differential diagnosis?
- 2) What features differentiate an aggressive bone lesion from a non-aggressive lesion?
- 3) What clinical information is particularly useful in differentiating primary bone lesions from metastatic ones.



# Case 10

55 yr old patient admitted to the surgical ward develops worsening abdominal pain

Questions:

- 1) What is the diagnosis?
- 2) What might you see on the corresponding CXR?
- 3) Name four common causes for this condition.

