

# **Medical Student Radiology Workbook**

## **Answer sheet**

### **Contents**

<b>Cardiothoracic Long Case</b>	<b>page 2</b>
<b>Interventional Radiology</b>	<b>page 3</b>
<b>MSK Long Case</b>	<b>page 10</b>
<b>Radiation Protection and Safety</b>	<b>page 11</b>
<b>Radiographer, The Role of</b>	<b>page 12</b>
<b>Radiology Quiz</b>	<b>page 13</b>
<b>Radionuclide Radiology</b>	<b>page 17</b>
<b>Radiograph, A short Guide</b>	<b>page 17</b>
<b>Request Card Task</b>	<b>page 18</b>
<b>Fluoroscopy</b>	<b>page 20</b>

# **Cardiothoracic Long Case**

**Author: Dr Aussami Abbas  
Radiology SpR**

## **SLIDE ONE**

- 1. What does the CXR show?**
- 2. What is the most likely diagnosis?**
- 3. Name three risk factors for this condition?**
  - 1.**
  - 2.**
  - 3.**
- 4. What clinical sign is associated with this condition?**
- 5. What further investigation will you request?**

## **SLIDE TWO**

- 6. How has this scan been acquired?**
- 7. What does it show?**
- 8. How do you classify this condition?**
- 9. What would you do next?**

# **Interventional Radiology**

**Author: Dr Liam Ingram  
Radiology SpR**

1. The Interventional Radiologist needs to master one technique which is the basis for almost all of our procedures. You may have already used it/seen it on the wards. This is called the SELDINGER technique.

Write or draw a brief description of the Seldinger technique:

2. Most IR procedures involve fluoroscopy or 'screening'

(i) What is fluoroscopy?

(ii) Can you think of other examples of when it is used Radiology?

(iii) What allows us to 'see' blood vessels and what is important to check before using it?

3. A whole group of IR procedures involve 'embolisation'.

(i) What does this mean?

(ii) Can you think of any groups of embolic materials?

(iii) What does 'non-target' embolisation mean, and why is it bad news?

## Cases

### Case 1: The blue patient.

Boris is 56, a lorry driver who is overweight and spends a lot of time sitting for long journeys. One day he notices that his calf becomes swollen, a little red and becomes painful. He goes to his GP who sends him to AMU.

(i) What do you think the diagnosis is?

(ii) What is the best radiological examination to confirm your suspicion?

At this stage Boris is haemodynamically stable and not short of breath. He is started on anti-coagulation therapy and is discharged home. A few weeks later, despite his INR being in the therapeutic range, he develops sudden onset pleuritic chest pain, shortness of breath, feels generally unwell and is hypoxic. He attends the Emergency department who suspect he has suffered a pulmonary embolus (PE). His CXR is normal.

(iii) What imaging options are available for confirming this diagnosis?

(iv) If patient has a confirmed PE whilst on treatment dose anti-coagulation, what IR option is available for protecting against further PEs?

(v) Where would you use your Seldinger technique to obtain vascular access and implant this device?

(vi) See Image 1: this is a pig tail catheter contrast flush run of the IVC. The level of a particular pair of important vessels must be located, one is labeled as (A), what is it?

(vii) Image 2: shows your implantable device in situ with and without contrast. These are usually temporary, sometimes they are permanent. How can we remove it? Can you see anything on the device which may help?

(viii) Image 3: this shows a common problem where the device has been deployed and has 'tilted,' this makes removal difficult. Any ideas about how it can be straightened? (see image 4 (a))

(ix) Can you think of any other indications for this device, other than recurrent PE on anti-coagulation?

#### Case 2: The green patient.

George is an 89 year man who has 60 pack years smoking history, has type II diabetes, ischaemic heart disease, hypertension and is blind in one eye. She has a long history of infected and poorly healing ankle ulcers on her right leg.

(i) Name three non-invasive imaging methods which could be used to interrogate this patient's lower limb arteries?

(ii) Case 2: Images 1 & 2 – this shows a normal lower limb angiogram from a common femoral artery (CFA) access. Now look at Image 3 of George, how are his vessels different? Can you name the vessels A-C?

(iii) Can you see a major abnormality which could be treated to improve flow to the patient's ankle?

(iv) How could you improve flow?

(v) Image 4: What are the tibial vessels like (i.e. the patient's run off, there should be 3! See the normal angiogram (images 1 and 2)?

Image 5 shows the result of your procedure.

Case 3: The red patient.

Ralph is 17 and sees his GP who refers him to a Urologist because he has felt what feels like 'a bag of worms' in the left side of his scrotum. It causes him some discomfort and would like it treated.

(i) Which imaging investigation is best to assess his scrotum?

(ii) Image 1: This is the result of your investigation, what do you think it shows?

(iii) Why does it usually occur on the left side?

(iv) What IR treatment option is available?

(v) Where would you use your Seldinger technique to gain access?

Image 2: Which vessel is A?

(vi) Image 3: This is the abnormally enlarged vessel causing all the trouble, what is it

(B)? Image 4 shows the result of your treatment.

Case 4: The yellow patient.

Yasmin is 35 and has many years of alcohol abuse. She has cirrhosis of her liver with several admissions due variceal bleeding and decompensated liver failure. She has regular ascitic drainages to relieve tense ascites. She has portal hypertension and the Hepatologists have tried several therapies and have now requested assistance by IR.

(i) The liver has a 'dual' blood supply, what vessel provides 2/3 of the blood supply to the liver?

(ii) What are the 3 main smaller vessels which combine to form this main vessel?

(iii) When the pressure in the portal venous system increases, porto-systemic shunts occur causing varices, can you think of any sites of variceal formation and hence bleeding? Image 1: shows two slices of her CT scan through her liver, note the varices, ascites and shrunken nodular cirrhotic liver.

(iv) To reduce portal pressure, IR can form a tract/shunt between the systemic blood system and the portal venous system called a TIPSS, what does this acronym mean?

(v) As the name suggests, the right internal jugular vein is usually used to gain access to the vena cava then right or middle hepatic veins (see image 2). How do you think access to the portal system is achieved (see image 3!)?

(vi) Now that you have accessed the portal system, how do you keep it open (see image 4)?

(vii) As seen on the CT, once the portal system is accessed large varices are visualised which may become a source of bleeding (haematemesis in this case). How can we fix those (see image 5)?

#### Case 5: The white patient.

Wilfred is a 72 year old male who has been involved in a road traffic collision at 70mph. He has obtained multiple blunt force injuries and is transferred to the Emergency department. He was initially unstable but after resuscitation he stabilised and the Emergency department performs a F.A.S.T scan in resus. They find some fluid around the liver and proceed by requesting a multi-trauma CT scan.

(i) What is a F.A.S.T scan?

(ii) What important findings are shown in this CT image (image 1)?

A.

B.

(iii) The IR Consultant has been asked to provide emergency treatment, what procedure should be performed?

(iv) You have gained access into the right CFA and navigate to the coeliac axis. What three vessels make up the conventional coeliac axis?

(v) A contrast run was performed (image 2), what is the arrow pointing at?

(vi) A super-selective micro catheter was passed into the area of abnormality and coiled as shown in image 3. Why can you embolise parts of liver and it not be too troublesome for the patient (think back to the case of the yellow patient!)?

**Well done!**

# **MSK Answer Book**

**Author: Dr Neeraj Purohit  
Radiology SpR**

- 1. What orthopaedic operation has the patient had before?**
- 2. What is a possible cause for the right hip pain?**
- 3. What is the diagnosis?**
- 4. What further imaging tests would you suggest in this case?**
- 5. What further investigations should the patient have?**
- 6. What operation might the patient have for her fractured neck of femur and why?**
- 7. How might this patient be anaesthetised?**
- 8. What is the diagnosis?**

# **Radiation Protection and Safety**

**Author: Dr Georgie Matthews  
Radiology SpR**

**1) Put these organs in an order of how susceptible they are to radiation:**

**stomach bone testes lung brain skin breast**

**2) By how many times is a CT chest dose higher than a plain chest X-ray?**

**3) What would be the most appropriate imaging to request in a case of?**

**17 year old female patient with right iliac fossa pain  
? Appendicitis  
? Ovarian Cyst  
bHCG –ve**

# **The Role of the Radiographer**

**Author: Clare Hawkins  
Superintendent Radiographer**

- 1. Which fish bones are visible on x-rays and why?**
- 2. What is the dose of a chest radiograph, abdominal radiograph, hand radiograph, CT abdomen, contrast swallow?**
- 3. What are the background radiation dose equivalents to the above?**
- 4. What is the advantage of a high KVp chest x-ray technique?**
- 5. What is the difference between CR and DR radiography?**
- 6. What is the impact on radiation dose of the general public of the above?**
- 7. What are the radiographic signs of a bowel perforation on a supine AXR?**
- 8. How would you know the difference between a PA and AP chest radiograph and why would you need to know?**
- 9. What are IRMER and IRR99? What is the difference?**
- 10. What is the patient identification protocol prior to ionising radiation exposure?**
- 11. What is the name of the council responsible for the registration of radiographers**

# **Radiology Quiz Answer Sheet**

**Author: Dr Aussami Abbas  
Radiology SpR**

## **CASE ONE**

- 1) What is the diagnosis?**
- 2) Name two possible complications.**
- 3) What might you see on the corresponding CXR?**
- 4) Name four common causes for this condition.**

## **CASE 2**

- 1) What is the diagnosis?**
- 2) What is the clinical deformity associated with this injury called?**
- 3) Name 2 methods of providing local anaesthesia for manipulation of this injury**
- 4) What degree of misalignment is acceptable following reduction?**

## **CASE 3**

- 1) Name 3 causes for the appearance of a hemi thorax “white out” on CXR**
  - 1.**
  - 2.**

**3.**

**2) How can you tell the difference between these 3 causes?**

**3) What is the diagnosis in this case?**

**4) What management should the patient have?**

**CASE 4**

**1) What is the diagnosis?**

**2) What is the most likely cause?**

**3) After ensuring the patient is clinically stable what further management would you arrange?**

**CASE 5**

**1) What is the diagnosis?**

**2) Which infectious organism is this associated with?**

**CASE 6**

**1) What is the diagnosis?**

**2) Is this the cause of the patient's symptoms?**

**3) Name three complications associated with this condition?**

**1.**

2.

3.

**4) Name three other common sites of disease involvement?**

1.

2.

3.

#### **CASE 7**

**1) What is the main abnormality?**

**2) What instructions should you give the nursing staff on the ward?**

**3) What surgery has the patient had in the past?**

#### **CASE 8**

**1) What is the diagnosis?**

**2) Name four potential causes?**

1.

2.

3.

4.

**3) What is the most likely cause in this case?**

### **CASE 9**

- 1) What is the differential diagnosis?**
- 2) What features differentiate an aggressive bone lesion from a non-aggressive lesion?**
- 3) What clinical information is particularly useful in differentiating primary bone lesions from metastatic ones?**

### **CASE 10**

- 1) What is the diagnosis?**
- 2) What might you see on the corresponding CXR?**
- 3) Name four common causes for this condition.**
  - 1.**
  - 2.**
  - 3.**
  - 4.**

**(End of Quiz)**

# **Radionucleotide Radiology**

**Author: Dr Mike Kay  
Radiology SpR**

**This is a read only module – there are no questions for you to complete. Make a note of any questions you may wish to ask in your workbook tutorial session.**

## **The Radiograph, A Short Guide**

**Author: Clare Hawkins, Superintendant Radiographer**

**This is a read only module – there are no questions for you to complete. Make a note of any questions you may wish to ask in your workbook tutorial session.**

# **Request Card Task**

**Author: Dr Sam Leach  
Radiology SpR**

## **CASE 1**

**What differential diagnoses are most likely?**

**Which investigation is most appropriate?**

## **CASE 2**

**What differential diagnoses are most likely?**

**Which investigation is most appropriate?**

## **CASE 3**

**What differential diagnoses are most likely?**

**Which investigation is most appropriate?**

**What problem might this investigation pose in this patient?**

## **CASE 4**

**What differential diagnoses are most likely?**

**Which investigation is most appropriate?**

### CASE 5 – Long Case

**This is a typical radiology request card. You may be expected to request investigations electronically. Fill out the request form for this patient with the most appropriate investigation, including differential diagnoses.**

SURNAME		FORENAMES		M/F	RADIOLOGY				
ADDRESS (Incl. Postcode and Telephone No.)					PREVIOUS X-RAYS				
					PREVIOUS NAME				
DATE OF BIRTH		HOSPITAL INDEX No.			APPOINTMENT				
WALKING <input type="checkbox"/>		CHAIR <input type="checkbox"/>		WARD/CLINIC	CONSULTANT/GENERAL PRACTITIONER	DATE			
TROLLEY <input type="checkbox"/>		PORTABLE <input type="checkbox"/>				TIME			
CLINICAL DETAILS & PROBLEM					PRIVATE	TICK	PREGNANT YES/NO  INITIALS <div></div>		
					CAT II				
					N H S				
					OTHER				
EXAMINATION SUGGESTED				DATE		BLEEP NUMBER			
				SIGNATURE (Junior Staff also Print Name)					
St Elsewhere Hospital Trust				WNU418					

# Fluoroscopy Module Answer Sheet

Radiology SSU Workbook  
Author: Katherine Garforth-COx

## Test 1: Terms used

Match the word to the description

Fluoroscopy

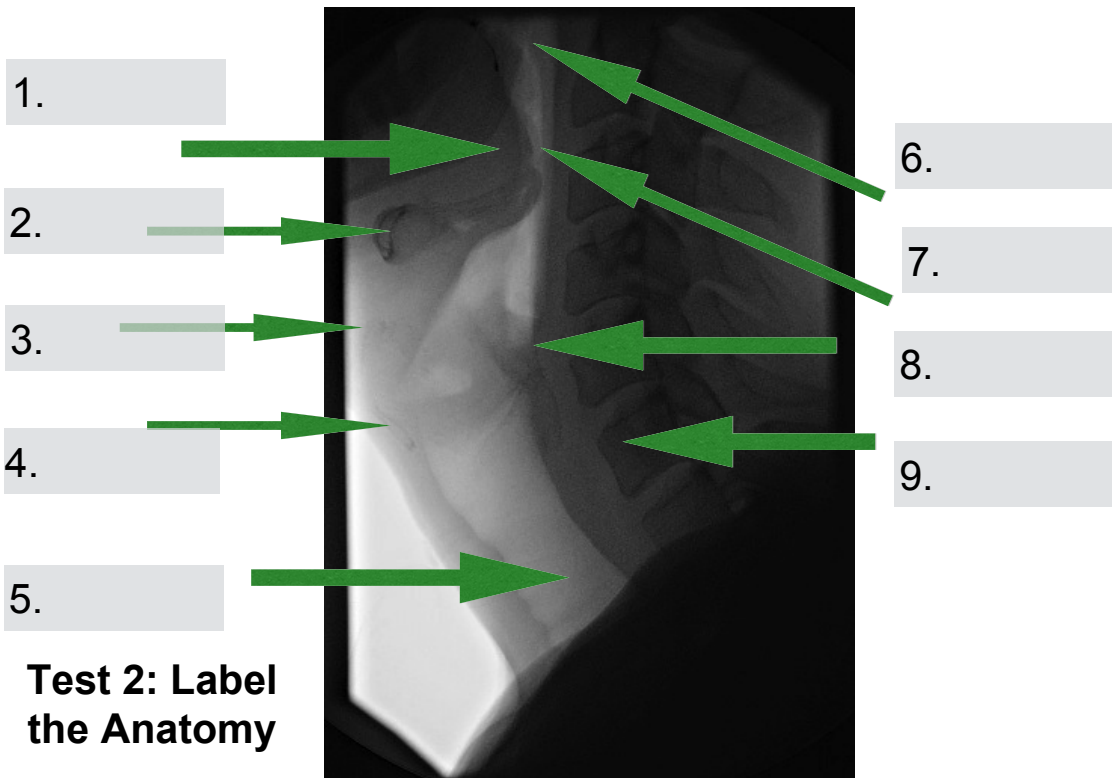
Single pulse of radiation at high mA  
resulting in low-noise image

Fluoro grab

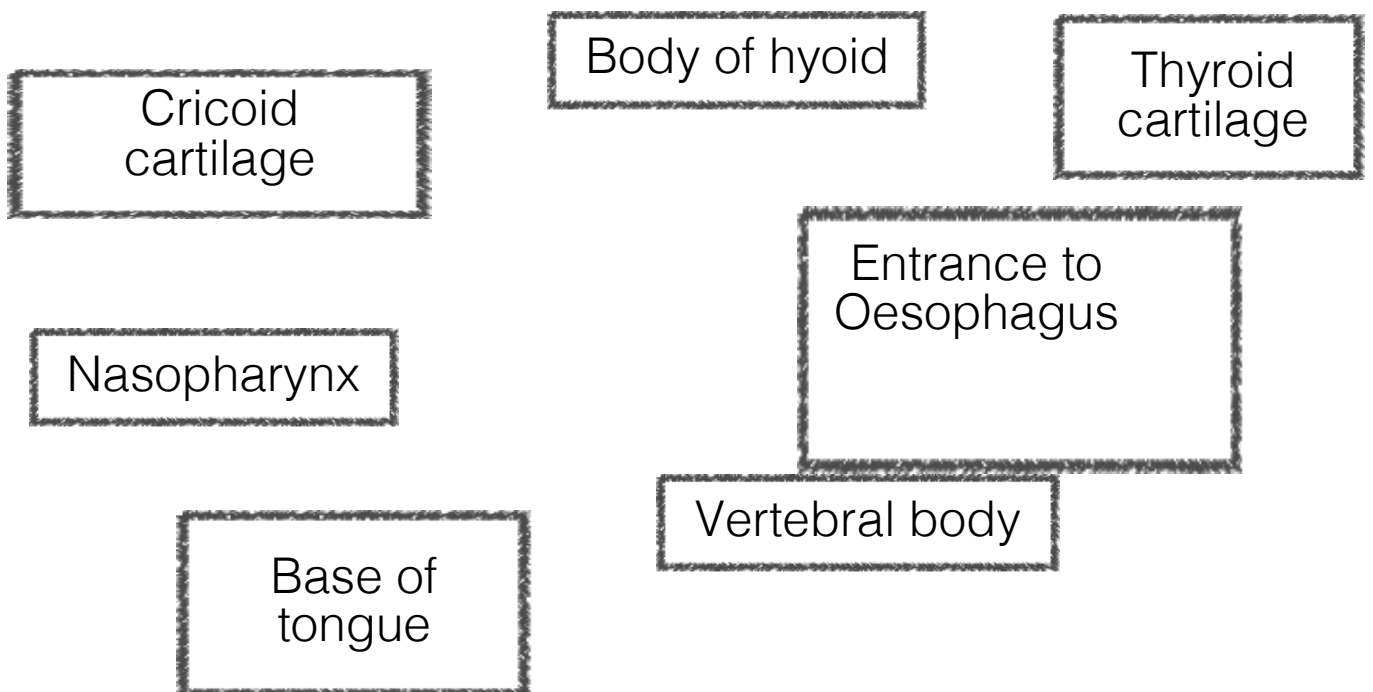
High noise image with  
X-ray beam on

Digital spot images  
(Acquisition)

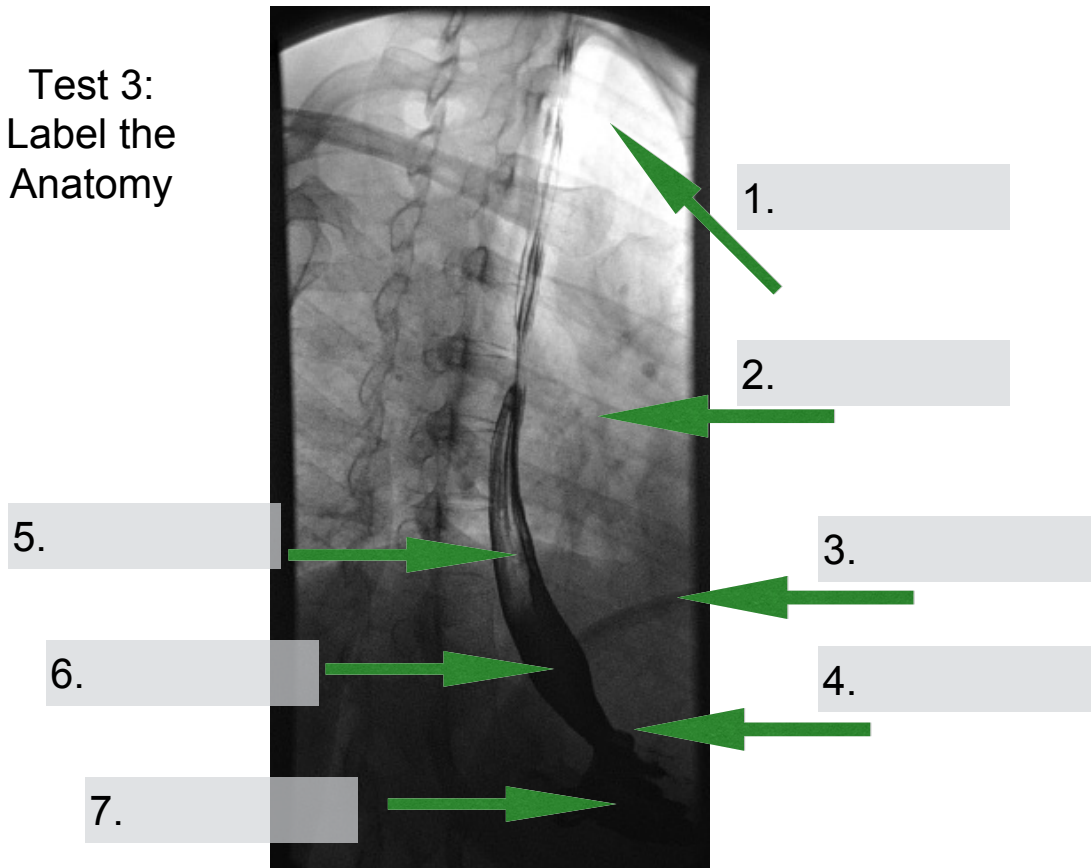
High noise image with  
X-ray beam off



(Labels below )



Test 3:  
Label the  
Anatomy



Labels – test 3

Diaphragm

Stomach

Contrast

Rib

Gastro-  
oesophageal  
junction

Oesophagus

Lung